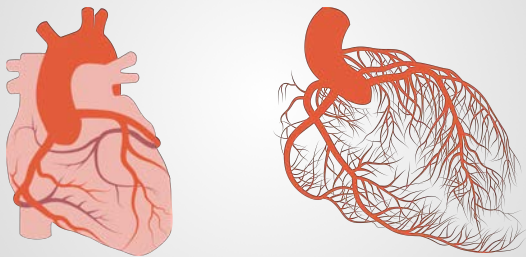




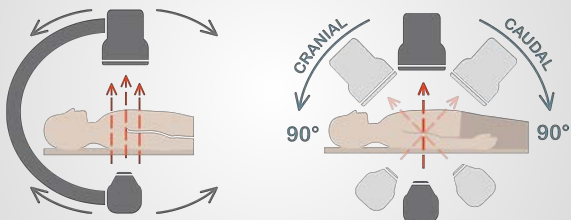
Conclusion

What have we learned?

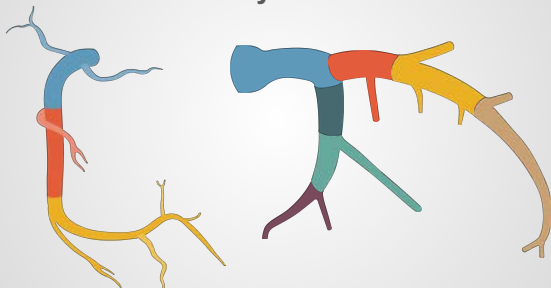
Coronary anatomy



Technical basics



Coronary arteries



Assessment of a stenosis?

